

## ORIGINAL ARTICLE

# Transcatheter Arterialization of Deep Veins in Chronic Limb-Threatening Ischemia

Mehdi H. Shishehbor, D.O., M.P.H., Ph.D., Richard J. Powell, M.D., Miguel F. Montero-Baker, M.D., Anahita Dua, M.D., Jorge L. Martínez-Trabal, M.D., Matthew C. Bunte, M.D., Arthur C. Lee, M.D., Andrew S. Mugglin, Ph.D., Joseph L. Mills, M.D., Alik Farber, M.D., and Daniel G. Clair, M.D., for the PROMISE II Investigators\*

## ABSTRACT

**BACKGROUND**

Approximately 20% of patients with chronic limb-threatening ischemia have no revascularization options, leading to above-ankle amputation. Transcatheter arterialization of the deep veins is a percutaneous approach that creates an artery-to-vein connection for delivery of oxygenated blood by means of the venous system to the ischemic foot to prevent amputation.

**METHODS**

We conducted a prospective, single-group, multicenter study to evaluate the effect of transcatheter arterialization of the deep veins in patients with nonhealing ulcers and no surgical or endovascular revascularization treatment options. The composite primary end point was amputation-free survival (defined as freedom from above-ankle amputation or death from any cause) at 6 months, as compared with a performance goal of 54%. Secondary end points included limb salvage, wound healing, and technical success of the procedure.

**RESULTS**

We enrolled 105 patients who had chronic limb-threatening ischemia and were of a median age of 70 years (interquartile range, 38 to 89). Of the patients enrolled, 33 (31.4%) were women and 45 (42.8%) were Black, Hispanic, or Latino. Transcatheter arterialization of the deep veins was performed successfully in 104 patients (99.0%). At 6 months, 66.1% of the patients had amputation-free survival. According to Bayesian analysis, the posterior probability that amputation-free survival at 6 months exceeded a performance goal of 54% was 0.993, which exceeded the prespecified threshold of 0.977. Limb salvage (avoidance of above-ankle amputation) was attained in 67 patients (76.0% by Kaplan–Meier analysis). Wounds were completely healed in 16 of 63 patients (25%) and were in the process of healing in 32 of 63 patients (51%). No unanticipated device-related adverse events were reported.

**CONCLUSIONS**

We found that transcatheter arterialization of the deep veins was safe and could be performed successfully in patients with chronic limb-threatening ischemia and no conventional surgical or endovascular revascularization treatment options. (Funded by LimFlow; PROMISE II study ClinicalTrials.gov number, NCT03970538.)

From University Hospitals Harrington Heart and Vascular Institute, Cleveland (M.H.S.); the Division of Vascular Surgery, Dartmouth–Hitchcock Medical Center, Lebanon, NH (R.J.P.); the Michael E. DeBakey Department of Surgery, Baylor College of Medicine, Houston (M.F.M.-B., J.L.M.); the Division of Vascular Surgery, Massachusetts General Hospital, Harvard Medical School (A.D.), and the Division of Vascular and Endovascular Surgery, Boston Medical Center, Boston University School of Medicine (A.F.) — both in Boston; the Division of Vascular Surgery, Ponce Health Sciences University, St. Luke's Episcopal Hospital, Ponce, Puerto Rico (J.L.M.-T.); Saint Luke's Mid America Heart Institute, Kansas City, MO (M.C.B.); HCA Florida North Florida Hospital, the Cardiac and Vascular Institute, Gainesville (A.C.L.); Paradigm Biostatistics, Anoka, MN (A.S.M.); and the Department of Vascular Surgery, Vanderbilt School of Medicine, Nashville (D.G.C.). Dr. Shishehbor can be contacted at mehdi.shishehbor@uhhospitals.org or at University Hospitals Harrington Heart and Vascular Institute, 11100 Euclid Ave., Lakeside 3rd Fl., Cleveland, OH 44106.

\*A complete list of the PROMISE II trial investigators is provided in the Supplementary Appendix, available at NEJM.org.

N Engl J Med 2023;388:1171-80.

DOI: 10.1056/NEJMoa2212754

Copyright © 2023 Massachusetts Medical Society.

**CME**  
at NEJM.org

 A Quick Take  
is available at  
NEJM.org

**A**RTERIAL REVASCULARIZATION IS STANDARD care for patients with chronic limb-threatening ischemia, the most advanced form of peripheral artery disease.<sup>1-3</sup> In the United States, the annual prevalence and incidence of chronic limb-threatening ischemia in patients over the age of 40 years are estimated to be 1.33% and 0.35%, respectively, which translates to up to 1 million patients in the Medicare population alone.<sup>4,5</sup> Despite advances in surgical and endovascular treatment, up to 20% of patients with chronic limb-threatening ischemia are not candidates for revascularization (referred to here as no-option),<sup>5-7</sup> primarily owing to the lack of an arterial target for distal runoff or an appropriate conduit for surgical bypass. Without the restoration of blood flow, no-option chronic limb-threatening ischemia that is characterized by pain, non-healing wounds, and gangrene will progress to major (above-ankle) amputation in most cases.<sup>8,9</sup> Major amputation for chronic limb-threatening ischemia is associated with 50% mortality within a year after amputation in patients over 65 years of age; mortality is higher among patients with coexisting cardiovascular conditions.<sup>10</sup>

Transcatheter arterialization of the deep veins is an endovascular revascularization procedure for the treatment of no-option chronic limb-threatening ischemia.<sup>11</sup> When the procedure is performed in the lower limbs, an arteriovenous fistula is created proximal to the diseased tibial arteries with the use of a covered stent. The oxygenated blood is then diverted from the tibial arteries to the tibial veins to bypass the severely diseased arterial vasculature. The venous system is leveraged to deliver oxygenated arterial blood to the foot through the pedal veins, which potentially averts major amputation and promotes wound healing. The PROMISE I study established the feasibility of transcatheter arterialization of the deep veins for the treatment of no-option chronic limb-threatening ischemia.<sup>11</sup> We performed the PROMISE II study to expand on this work to evaluate the effect of the procedure on amputation-free survival and limb salvage as compared with an objective performance goal.

## METHODS

### STUDY DESIGN

PROMISE II was a prospective, single-group, multicenter study to evaluate the safety and effective-

ness of transcatheter arterialization of the deep veins against an objective performance goal. The protocol (available with the full text of this article at NEJM.org) was designed by the sponsor (LimFlow) with input from the principal investigators and approved by the Food and Drug Administration (FDA) and the institutional review board at each site. An investigational device exemption was approved by the FDA. All the patients provided written informed consent.

Clinical events were adjudicated by an independent committee, and an independent data and safety monitoring committee provided oversight. An independent core laboratory reviewed all wound images. Analyses were performed by the North American Science Association (a contract research organization) and Paradigm Biostatistics (committees are described in the Supplementary Appendix, available at NEJM.org). The authors had unrestricted access to the data; the first author wrote the first draft of the manuscript, and all the authors provided critical review. All the authors vouch for the accuracy and completeness of the data and for the fidelity of the study to the protocol. No agreements existed between the sponsor and the authors and their institutions regarding confidentiality of the data, and the outcomes were to be published regardless of the results.

### PATIENT POPULATION

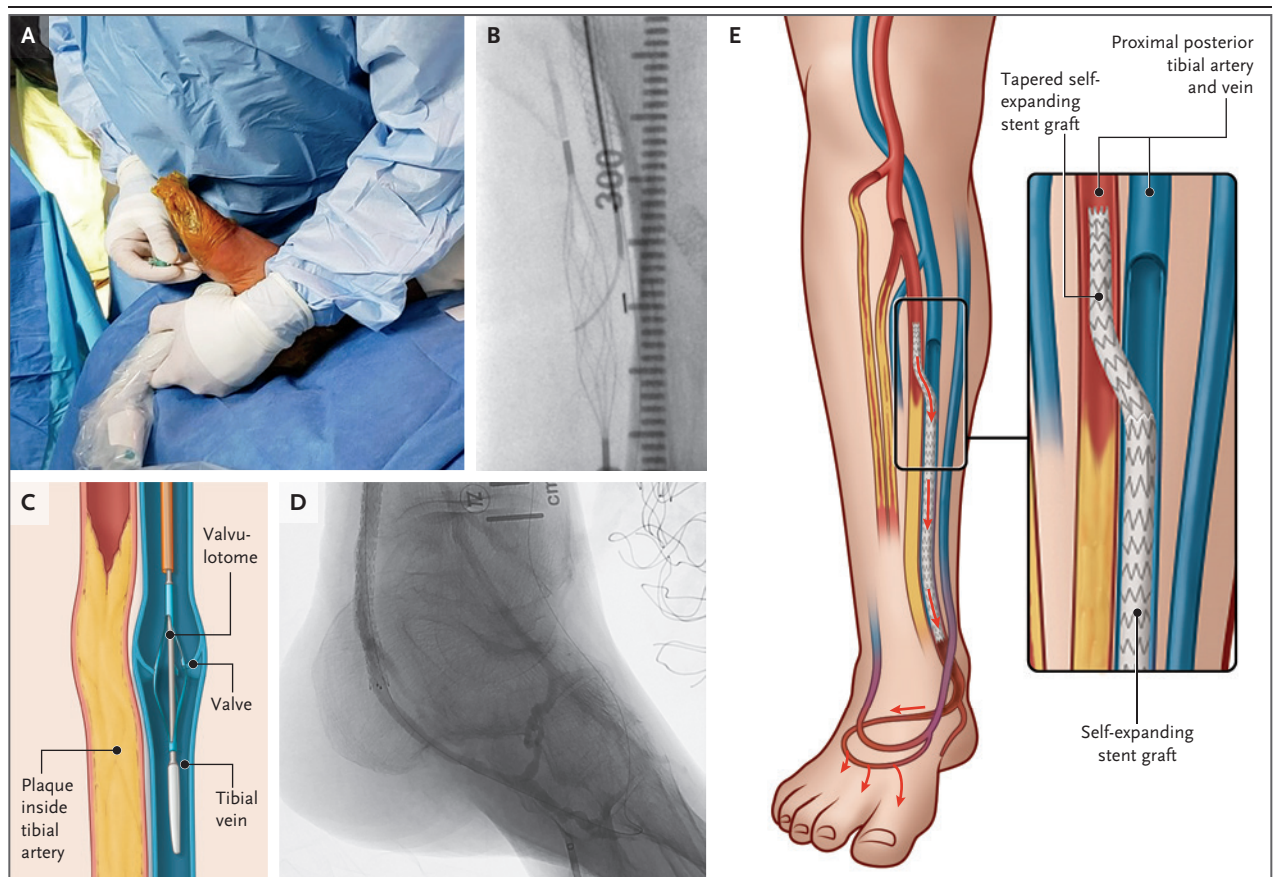
Patients with chronic limb-threatening ischemia with no option for arterial revascularization were recruited and screened for eligibility on the basis of lower-limb angiography, vein mapping, and prespecified study inclusion and exclusion criteria (described in the Supplementary Appendix). Before enrollment, an independent physician review committee confirmed each patient's no-option status, defined as either the absence of a pedal artery target for endovascular or surgical therapy or the absence of a viable single segment of an autogenous vein conduit despite the presence of a pedal artery target that could receive a graft. Follow-up visits were scheduled at 2 weeks; at 1, 2, 3, 6, 9, and 12 months for the first year; and annually to year 3. The study team at each site was multidisciplinary and included vascular specialists and wound-care experts working in collaboration.

Patients with Rutherford class 5 (tissue loss or focal gangrene) or 6 (extensive gangrene) chronic

limb-threatening ischemia were eligible for enrollment; scores on the Rutherford scale range from 0 to 6, with higher numbers indicating worse disease. Patients with dialysis-dependent chronic kidney disease were included if they had autogenous access or were receiving peritoneal dialysis and met the criteria for clinical stability. Patients with systemic infection, rapidly deteriorating wounds, or advanced heart failure were excluded. The index transcatheter arterialization procedure was not permitted within 30 days after an earlier revascularization procedure to prevent confounding; however, endovascular procedures to provide access to the arterial segment proximal to the transcatheter arterialization circuit were allowed during the index procedure.

#### TREATMENT AND PROCEDURAL STEPS

The procedure involved the use of the LimFlow System (LimFlow), and all study physicians who performed the procedure received didactic and hands-on training. Before undergoing the procedure, patients received dual antiplatelet therapy, and the patency, diameter, and tortuosity of the lateral plantar veins were assessed with the use of duplex ultrasound. The lateral plantar vein was accessed through the plantar surface with the use of ultrasound guidance and standard Seldinger technique (Fig. 1). A wire was advanced from the lateral plantar vein to the proximal posterior tibial vein adjacent to the tibial artery that would be used for arterialization in the leg. The ipsilateral common femoral artery was then accessed



**Figure 1.** Key Procedural Steps for Transcatheter Arterialization of the Deep Veins.

The steps for transcatheter arterialization of the deep veins in the lower leg involve obtaining ultrasound-guided pedal vascular access (Panel A); advancing the needle into the mesh cage for establishment of arteriovenous crossing (the needle is in the arterial system and advances through the artery into the vein; the basket is in the vein) (Panel B); rendering venous valves incompetent with a push valvulotome (Panel C); deploying a straight covered stent at the level of the calcaneus (Panel D); and lining the vein with straight stents before placing a tapered, self-expanding, covered stent across the arteriovenous crossing to establish arterial blood flow in the venous system (Panel E).

with the use of an antegrade technique. The arterial and venous catheters were introduced into the common femoral artery and lateral plantar vein, respectively, and advanced to the desired crossing point, typically the proximal posterior tibial artery and a paired posterior tibial vein. With the use of a reentry catheter, the reentry needle was deployed from the artery into the mesh snare of the venous catheter that was positioned in parallel. A wire was then advanced and externalized through the pedal venous access site, which created through-and-through access. The arterial catheter was removed, and the artery-to-vein crossover point was dilated. The forward-cutting, coaxial valvulotome was inserted and advanced into the tibial vein to midfoot to render the venous valves incompetent. After successful valvulotomy, balloon dilatation of the tibial vein to the ankle was performed to avoid compression of the to-be-placed covered stent graft. The self-expanding stent grafts were deployed in the target vein from the cephalad calcaneal border to just distal of the crossover point. The procedure was completed with the placement of a tapered self-expanding stent graft across the artery-to-vein crossing point, and angiographic confirmation of adequate venous pedal outflow was obtained. Dilatation of the pedal venous loop was performed as needed to ensure adequate distal venous perfusion. Patients were prescribed dual antiplatelet or anticoagulant therapy for at least 3 months after undergoing the procedure.

#### PRIMARY AND SECONDARY END POINTS

The primary end point was amputation-free survival, defined as a composite of freedom from above-ankle amputation or death from any cause at 6 months. Secondary end points were primary patency of the transcatheter arterialization circuit (defined as the absence of occlusion of the endovascular intervention without the need for additional intervention), primary-assisted patency (the absence of occlusion of the endovascular intervention with the use of additional intervention, as long as occlusion of the primary treated site had not occurred), or secondary patency (absence of occlusion of the endovascular intervention that was maintained with the use of additional procedures after an occlusion occurred); limb salvage; change in Rutherford classification; technical and procedural success; healing of the target wound and all wounds; and wound area at

30 days and 6 months after the procedure. (Detailed descriptions of the secondary end points are provided in the Supplementary Appendix.) In addition, freedom from contrast-induced nephropathy, procedure time, radiation exposure, and contrast volume were collected periprocedurally. Serious adverse events (defined as events that were life-threatening; resulted in death, hospitalization, disability, or congenital abnormality; or necessitated an intervention) were reported by the investigators, reviewed by an independent medical monitor, and adjudicated by the clinical events committee.

#### STATISTICAL ANALYSIS

We used a Bayesian Goldilocks adaptive design for sample-size determination,<sup>12</sup> with possible sizes of 60, 75, 90, and 105 patients, which provided the study with at least 80% power when the probability of amputation-free survival was at least 0.68 and 90% power when the probability was at least 0.70. The statistical analysis plan allowed for early stopping of enrollment if amputation-free survival was very high or very low. Enrollment was concluded at 105 patients.

The primary end point of amputation-free survival at 6 months was evaluated against a prespecified performance goal of 54%, derived from the upper boundary of the confidence interval of 42% amputation-free survival reported among the patients with no-option chronic limb-threatening ischemia (descriptions of statistical analyses are provided in the Supplementary Appendix).<sup>9</sup> We assigned a uniform prior distribution for amputation-free survival at 6 months and updated that distribution on the basis of binary outcomes. We accounted for the effect of missing data with the use of multiple imputation. The standard of study success was a posterior probability exceeding 0.977, which controlled the false positive rate for the study at 0.025.

Prespecified subgroup analyses of sex, dialysis status, age ( $\leq 70$  years or  $> 70$  years), presence of diabetes, race, ethnic group, and Rutherford class were performed. The effect of coronavirus disease 2019 (Covid-19) on patient mortality was considered, and a sensitivity analysis was performed. Baseline categorical variables were summarized with the use of descriptive statistics, including the number of observations and percentages. Continuous variables were summarized as medians with interquartile ranges. Kaplan–

Meier estimates were used to calculate time-to-event variables. Because the statistical analysis plan did not include a provision for correcting for multiplicity when conducting tests for secondary or other outcomes, results are reported as point estimates only. Data preparation and statistical analyses were performed with the use of SAS software, version 9.4 (SAS Institute), and R software, version 3.6.1 (R Project for Statistical Computing).

## RESULTS

### PATIENTS AND PROCEDURAL CHARACTERISTICS

Between December 2019 and March 2022, a total of 219 patients underwent screening, and 105 were enrolled in the study across 20 sites in the United States (Fig. S1 in the Supplementary Appendix). The median age of the patients was 70 years (interquartile range, 38 to 89), 33 (31.4%) were women, and 45 (42.8%) were Black, Hispanic, or Latino. Most patients had several preexisting conditions associated with chronic limb-threatening ischemia, including diabetes, hypertension, and dyslipidemia, and 78 patients (74.3%) had undergone previous revascularization procedures on the index limb (Table 1). All the patients presented with a nonhealing ulcer or frank gangrene and were classified as Rutherford class 5 (68 patients) or class 6 (37 patients). Our study included 19 patients with dialysis-dependent chronic kidney disease (18.1%) who had either a stable arteriovenous fistula or were receiving peritoneal dialysis. A total of 102 patients (97.1%) with no treatment option had no runoff target for traditional intervention, and 3 (2.9%) did not have a usable autogenous conduit.

The transcatheter arterialization procedure was technically successful in 104 of 105 patients (99.0%), with no unanticipated adverse device events. The patient who did not have a successful procedure was followed for safety through 6 months and withdrew from the study as prespecified in the protocol. The posterior tibial artery was the most common target for arteriovenous crossing location (75.2%), followed by the peroneal artery (19.0%) and the tibioperoneal trunk (5.7%) (Table 2).

### END POINTS

Follow-up was completed in 102 of 105 patients (97.1%) at 6 months (1 patient was lost to follow-

**Table 1. Characteristics of the Patients at Baseline.\***

Characteristic	All Patients (N = 105)
Median age (range) — yr	70 (38–89)
Male sex — no. (%)	72 (68.6)
Race — no. (%)†	
White	64 (61.0)
Black or African descent	16 (15.2)
Asian	2 (1.9)
Unknown or declined to state	23 (21.9)
Ethnic group — no. (%)†	
Not Hispanic or Latino	76 (72.4)
Hispanic or Latino	29 (27.6)
Median body-mass index (range)‡	26.2 (18.0–48.8)
History of smoking — no. (%)	44 (41.9)
Current	6 (5.7)
Former	38 (36.2)
Previous stroke — no. (%)	9 (8.6)
Previous myocardial infarction — no. (%)	24 (22.9)
Hypertension — no. (%)	96 (91.4)
Dyslipidemia — no. (%)	73 (69.5)
Diabetes mellitus — no. (%)	81 (77.1)
Type I	11 (10.5)
Type II	70 (66.7)
Chronic kidney disease — no. (%)	41 (39.0)
Dialysis — no. (%)	19 (18.1)
Rutherford classification — no. (%)§	
Stage 5	68 (64.8)
Stage 6	37 (35.2)
Previous intervention in target limb — no. (%)	78 (74.3)

\* Percentages may not total 100 because of rounding.

† Race and ethnic group were reported by the patient or abstracted from medical records.

‡ The body-mass index is the weight in kilograms divided by the square of the height in meters.

§ The Rutherford scale ranges from 0 to 6, with higher numbers indicating worse disease.

up, and 2 withdrew). A total of 23 patients underwent major amputation, and 12 died.

Amputation-free survival at 6 months (the primary end point) estimated by the mean of the posterior distribution was 0.66, with a 95% Bayesian credible interval of 0.565 to 0.745. The posterior probability that this rate exceeded the performance goal of 0.54 was 0.993, which was greater than the prespecified success criterion of 0.977. Amputation-free survival estimated with

**Table 2. Procedural Characteristics of Transcatheter Arterialization of the Deep Veins.\***

Characteristic	All Patients (N=105)
Technical success — no. (%)	104 (99.0)
Arteriovenous crossing target vein location — no. (%)	
Peroneal vein	6 (5.7)
Posterior tibial vein	99 (94.3)
Arteriovenous crossing target artery location — no. (%)	
Peroneal artery	20 (19.0)
Posterior tibial artery	79 (75.2)
Tibioperoneal trunk	6 (5.7)
Reintervention within 6 mo after procedure — no./total no. (%)	38/104 (36.5)

\* Percentages may not total 100 because of rounding.

the use of the Kaplan–Meier method was 66.1%. The percentages of limb salvage and survival were 76.0% and 87.1%, respectively (Fig. 2).

Prespecified subgroup analyses showed no material differences between the groups (Fig. S2), with the exception that 19 patients with dialysis-dependent chronic kidney disease had amputation-free survival of 36.8%, whereas the 86 patients who did not have dialysis-dependent chronic kidney disease had amputation-free survival of 72.7%. The mortality among patients who had dialysis-dependent chronic kidney disease was 36.2% as compared with 8.6% among patients who did not have dialysis-dependent chronic kidney disease.

At 6 months, the percentages of primary patency, primary-assisted patency, and secondary patency were 25.9%, 45.4%, and 64.2%, respectively. Repeat interventions to address native arterial disease and flow optimization within the transcatheter arterialization circuit occurred in 38 patients (36.5%). A decrease in Rutherford class was observed in 27 of 64 patients (42%). The median procedure time was 199 minutes, the median radiation exposure was 195 mGy, and the median amount of iodinated contrast used in the procedures was 127 milliliters. At 72 hours postprocedure, 103 patients (98.1%) were free from contrast-induced nephropathy. Procedural success (technical success with absence of death, major amputation, or reintervention at 1 month) occurred in 80 patients (76.9%) (Table S1).

## WOUND HEALING

The median primary wound area at baseline and at 6 months was 3.9 cm<sup>2</sup> (interquartile range, 1.7 to 9.3) and 1.0 cm<sup>2</sup> (interquartile range, 0.0 to 3.6), respectively. Since the study included patients with extensive gangrene and tissue loss, minor amputations, such as amputation of toes (40 amputations in 30 patients) and transmetatarsal amputations or revisions (51 in 41 patients) were allowed and expected. At 6 months, target wounds were completely healed in 16 of 63 patients (25%), and all wounds were completely healed in 24 of 86 patients (28%). Target wounds were categorized as being in the process of healing in 32 of 63 patients (51%) (Fig. 3 and Figs. S3, S4, and S5).

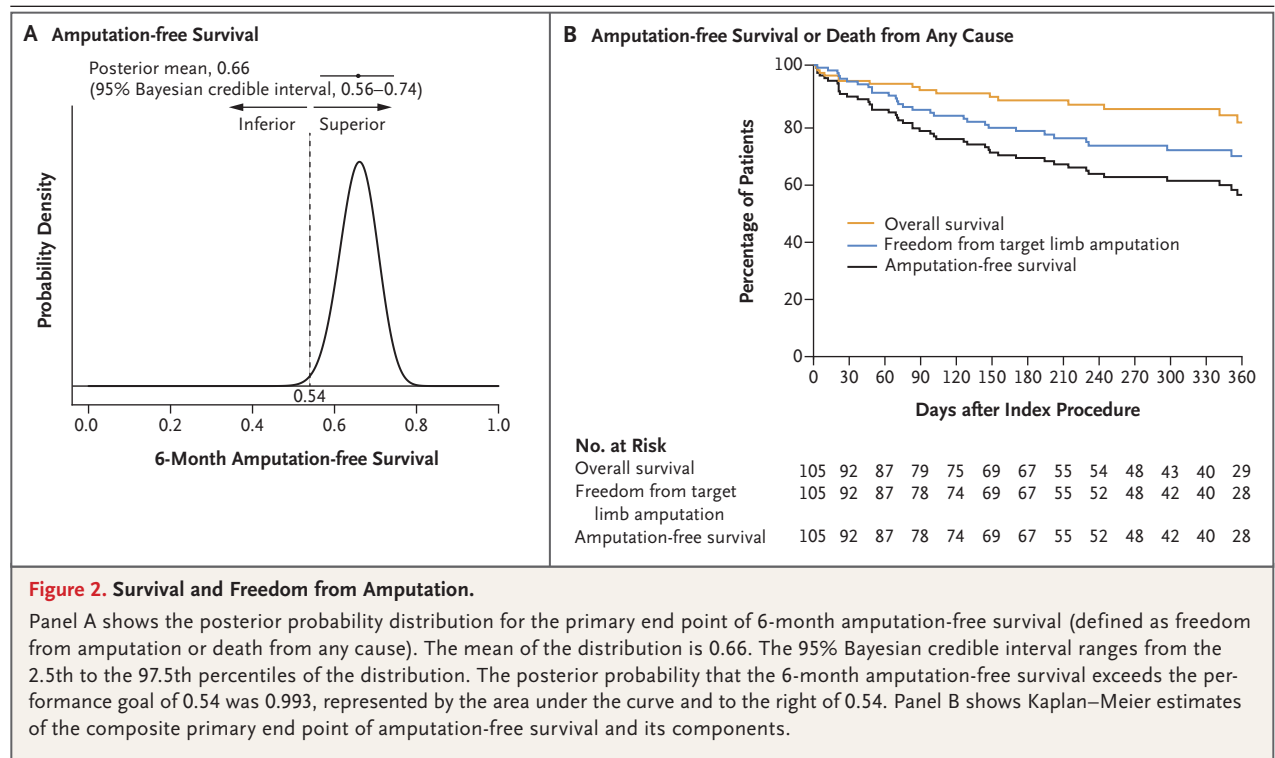
## ADVERSE EVENTS

No unanticipated adverse device-related events were reported. A total of 98 of 105 patients (93.3%) had an adverse event (Table S2).

## DISCUSSION

In this prospective study involving patients with chronic limb-threatening ischemia and no conventional surgical or endovascular revascularization treatment options, transcatheter arterialization of the deep veins was successfully performed in 104 of 105 patients (99.0%), was associated with 66.1% amputation-free survival, and improved wound healing with complete healing in 16 patients (25.4%) and partial wound healing in 32 patients (50.8%) at 6 months. Results appeared consistent among the subgroups, with the exception that among patients with dialysis-dependent chronic kidney disease, amputation-free survival occurred in a smaller proportion and death occurred in a greater proportion.

Relieving ischemia by arterializing the deep veins is not a new concept, having first been hypothesized and attempted more than 100 years ago and evaluated in multiple open surgical series.<sup>13–15</sup> However, the surgical technique was associated with several complications, including infection, deep incisions to create anastomosis, difficulty in lysing valves in the target vein, and difficulty in prevention of a steal phenomenon (diversion of blood flow away from the affected area) from venous branches at the calf and ankle.<sup>16</sup> Transcatheter arterialization addresses some of the limitations that resulted in failure in earlier surgical attempts. The transcatheter arteri-



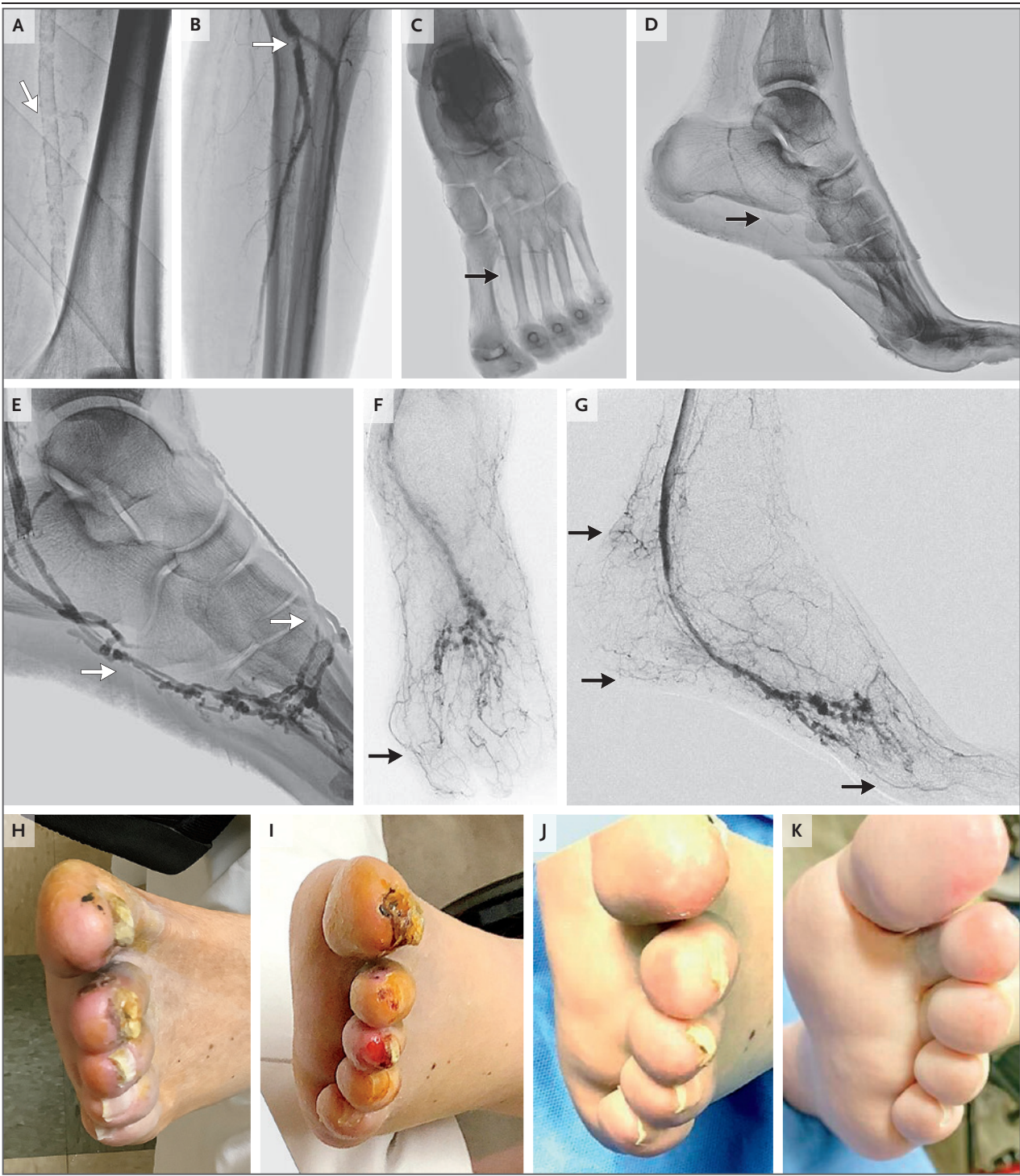alization endovascular technique circumvents an open incision and directs arterial blood to the pedal venous arch without diversion through the venous branches. Antegrade valvulotomy allows for the ablation of venous valves in the pedal loop that would otherwise hinder adequate blood flow to the distal foot. In addition, venous congestion as a side effect of the procedure has not been observed. The transcatheter arterialization procedure allows oxygenated blood to reach the distal foot by way of the venous system while addressing the limitations of surgical arterialization of deep veins.

Early prospective pilot studies in Singapore and Europe supported European Certificate of Conformity (known as the CE mark) approval and led to the PROMISE I early feasibility study in the United States.<sup>17–19</sup> Results across all studies were consistent, with the pilot studies that were performed outside the United States showing percentages of 6-month and 12-month amputation-free survival of 83.9% and 71.0%, respectively; 6- and 12-month amputation-free survival was 74% and 70%, respectively, in the PROMISE I study.<sup>11,19,20</sup> Patients who were enrolled in the PROMISE II study were representative of real-world patients (Table S3), including those with

dialysis-dependent chronic kidney disease and Rutherford class 5 or 6 wounds, who are routinely excluded from vascular device studies. Beyond the presence of routine coexisting conditions, including diabetes, 74.3% of the patients had a history of previous unsuccessful revascularization procedures of the index limb, which indicated that this complex cohort of patients included those with limb pain, nonhealing wounds, and gangrene who were probably at risk for major amputation.

Results of a prespecified subgroup analysis were aligned with those of previously published outcomes indicating an increased risk of death after peripheral arterial revascularization procedures among patients who were undergoing dialysis.<sup>21,22</sup> Although the incidence of limb salvage was similar between patients who had dialysis-dependent chronic kidney disease and those who did not, mortality appeared to be greater in the population with dialysis-dependent disease. The decision to offer transcatheter arterialization of the deep veins to patients with dialysis-dependent chronic kidney disease should take into consideration life expectancy and patient preferences.

An important aspect of the PROMISE II study was the analysis of the independent multidisci-



plinary physician review committee, which confirmed the patient's no-option status before enrollment. However, the presence of no-option chronic limb-threatening ischemia is associated with several variables beyond anatomy alone. Access to

subspecialty care, geographic location, and socioeconomic status all contribute to a real-world lack of peripheral artery revascularization and an increased incidence of major amputation. The transcatheter arterialization procedure may ad-



**Figure 3 (facing page). Transcatheter Arterialization in a Patient with Chronic Limb-Threatening Ischemia.**

A 72-year-old man with type II diabetes mellitus, hypertension, severely calcified peripheral arteries, and contralateral amputation due to chronic limb-threatening ischemia that was classified as Rutherford stage 5 (scale ranges from 0 to 6, with higher numbers indicating worse disease) with ulcers of the hallux and the second and third digits that were present for 24 months underwent transcatheter arterialization of the deep veins of his left foot. Panels A through D show baseline angiographic imaging that revealed calcified peripheral arteries (white arrows) and small-caliber plantar metatarsal vessels (black arrows) that were not amenable to traditional revascularization procedures. Panel E shows an angiogram obtained after the establishment of the transcatheter arterialization circuit, with some vessel spasm (white arrows) seen in the lateral plantar vein. Panels F and G show angiographic imaging at 24 months, which reveal newly appreciated vascular anatomy (black arrows) of the foot. Panels H through J show the progression of wound healing after transcatheter arterialization, and Panel K shows sustained healthy tissue at 24 months. Brightness was adjusted in the angiographic images to allow better visualization of the vasculature.

dress some of these issues by removing the anatomical barriers to revascularization by allowing for restoration of blood flow to the foot in patients who otherwise would have no option for treatment.

The increasing number of patients with chronic limb-threatening ischemia represents a large burden for the health care system and a reduced quality of life and life expectancy for patients. Major amputation results in loss of mobility and a host of secondary effects, including deconditioning, depression, and social isolation, and has

been associated with an increased risk of death.<sup>23</sup> Revascularization and limb salvage avert this trajectory and have been shown to be more cost effective than amputation.<sup>24</sup> The introduction of transcatheter arterialization provides the possibility of revascularization in patients with no-option chronic limb-threatening ischemia who previously were consigned to primary amputation, thus potentially reducing the resulting illness, death, and economic burden of amputation.

Our study has several limitations, including the lack of a control group; however, random assignment of patients destined for major amputation was practically and ethically unfeasible. The study continuously enrolled patients during the Covid-19 pandemic, with 12 reported infections and 5 deaths adjudicated by the clinical events committee as being related to Covid-19. In addition, transcatheter arterialization was performed by experienced interventional cardiologists and vascular surgeons who underwent training to perform the procedures, and the procedure may be available only at a specialist center. In addition, follow-up was limited to 12 months, and the number of patients dependent on dialysis was small.

We found that transcatheter arterialization of the deep veins was safe and could be performed with a high degree of procedural success in patients with chronic limb-threatening ischemia and no conventional surgical or endovascular revascularization options to promote wound healing and prevent major amputation.

Supported by LimFlow.

Disclosure forms provided by the authors are available with the full text of this article at NEJM.org.

A data sharing statement provided by the authors is available with the full text of this article at NEJM.org.

**REFERENCES**

- Conte MS, Bradbury AW, Kolh P, et al. Global vascular guidelines on the management of chronic limb-threatening ischemia. *Eur J Vasc Endovasc Surg* 2019; 58:Suppl 1:S1.e33-S109.e33.
- Gerhard-Herman MD, Gornik HL, Barrett C, et al. 2016 AHA/ACC guideline on the management of patients with lower extremity peripheral artery disease: executive summary: a report of the American College of Cardiology/American Heart Association Task Force on Clinical Practice Guidelines. *Circulation* 2017; 135(12):e686-e725.
- Shishehbor MH, White CJ, Gray BH, et al. Critical limb ischemia: an expert statement. *J Am Coll Cardiol* 2016;68: 2002-15.
- Nehler MR, Duval S, Diao L, et al. Epidemiology of peripheral arterial disease and critical limb ischemia in an insured national population. *J Vasc Surg* 2014;60(3):686-95.e2.
- Duff S, Mafilios MS, Bhounsule P, Hasegawa JT. The burden of critical limb ischemia: a review of recent literature. *Vasc Health Risk Manag* 2019;15:187-208.
- Wu HYP, Chen Y, Li Y, Cai C, Lv P. The current state of endovascular intervention for critical limb ischemia: a systematic review. *Vasc Invest Ther* 2021;4:46-53.
- Ferraresi R, Casini A, Losurdo F, et al. Hybrid foot vein arterialization in no-option patients with critical limb ischemia: a preliminary report. *J Endovasc Ther* 2019;26:7-17.
- Norgren L, Hiatt WR, Dormandy JA, et al. Inter-society consensus for the management of peripheral arterial disease (TASC II). *J Vasc Surg* 2007;45:Suppl S:S5-S67.
- Ghare MI, Pietras C, Tirziu D, et al. Chronic critical limb ischemia with no revascularization option: systematic review and meta-analysis. *J Crit Limb Ischem* 2021;1(3):E85-E92.
- Kristensen MT, Holm G, Kirketerp-Møller K, Krashennikoff M, Gebuhr P. Very low survival rates after non-traumatic lower limb amputation in a consecutive series: what to do? *Interact Cardiovasc Thorac Surg* 2012;14:543-7.
- Clair DG, Mustapha JA, Shishehbor MH, et al. PROMISE I: early feasibility

- study of the LimFlow System for percutaneous deep vein arterialization in no-option chronic limb-threatening ischemia: 12-month results. *J Vasc Surg* 2021;74:1626-35.
12. Broglio KR, Connor JT, Berry SM. Not too big, not too small: a Goldilocks approach to sample size selection. *J Biopharm Stat* 2014;24:685-705.
13. Lengua F. Arterialization technic of the venous net work in the foot. *Nouv Presse Med* 1975;4:1309-42.
14. Sheil GR. Treatment of critical ischaemia of the lower limb by venous arterialization: an interim report. *Br J Surg* 1977;64:197-9.
15. Szilagyi DE, Jay GD III, Munnell ER. Femoral arteriovenous anastomosis in the treatment of occlusive arterial disease. *AMA Arch Surg* 1951;63:435-51.
16. Ho VT, Gologorsky R, Kibrik P, et al. Open, percutaneous, and hybrid deep venous arterialization technique for no-option foot salvage. *J Vasc Surg* 2020;71:2152-60.
17. Kum S, Tan YK, Tang T, Schmidt A, Scheinert D, Ferraresi R. Percutaneous deep venous arterialization: a brief technical overview of a new therapy for treating end-stage “no-option” critical limb ischemia. *Endovascular Today*. May 2015 (<https://evtoday.com/articles/2015-may/percutaneous-deep-venous-arterialization>).
18. Kum S, Tan YK, Schreve MA, et al. Midterm outcomes from a pilot study of percutaneous deep vein arterialization for the treatment of no-option critical limb ischemia. *J Endovasc Ther* 2017;24:619-26.
19. Schmidt A, Schreve MA, Huizing E, et al. Midterm outcomes of percutaneous deep venous arterialization with a dedicated system for patients with no-option chronic limb-threatening ischemia: the ALPS multicenter study. *J Endovasc Ther* 2020;27:658-65.
20. Mustapha JA, Saab FA, Clair D, Schneider P. Interim results of the PROMISE I trial to investigate the LimFlow system of percutaneous deep vein arterialization for the treatment of critical limb ischemia. *J Invasive Cardiol* 2019;31:57-63.
21. Meyer A, Fiessler C, Stavroulakis K, et al. Outcomes of dialysis patients with critical limb ischemia after revascularization compared with patients with normal renal function. *J Vasc Surg* 2018;68(3):822.e1-829.e1.
22. Kotov A, Blasche DA, Peters F, et al. The impact of chronic kidney disease on mid-term outcomes after revascularisation of peripheral arterial occlusive disease: results from a prospective cohort study. *J Clin Med* 2022;11:4750.
23. Suckow BD, Bessen S, Hebb D, et al. Patients with chronic limb-threatening ischemia prioritize mobility over pain, support systems, wounds, or mental health. *J Vasc Surg* 2020;72(1):e32-e33.
24. Barshes NR, Koungias P, Ozaki CK, et al. Cost-effectiveness of revascularization for limb preservation in patients with marginal functional status. *Ann Vasc Surg* 2014;28:10-7.

Copyright © 2023 Massachusetts Medical Society.



In “Not Otherwise Specified,” Dr. Lisa Rosenbaum, cardiologist and national correspondent for the *New England Journal of Medicine*, defies our sound-bite culture to go deep with some of medicine’s most innovative thinkers. Her guests’ stories and ideas about health care’s toughest challenges and greatest promise may change the way you think about medicine, health, and society.

Listen to the latest episode, “Being Seen,” at [NEJM.org](https://www.nejm.org) or wherever you get your podcasts.